

## **Morphometric Analysis of Mental Foramen in Human Mandibles of South Gujarat:**

**Deepa Rani Agarwal, Sandeep B. Gupta**

Department of Anatomy, S.M. Institute of Medical Education & Research, Umarwada, Surat-395010

### **Abstract:**

Mental Foramen is found on the anterolateral aspect of the mandible and transmits mental nerves and vessels. The knowledge of anatomical morphometry of mental foramen is essential in clinical dentistry when administering regional anesthesia and performing periapical surgery in the mental region of the mandible. Mental nerve leaving the foramen is anesthetized during the dental procedures, suturing of soft tissue lacerations of mouth and biopsy. The aim of the study was to elucidate the morphological features and precise anatomical position of the mental foramen with reference to surrounding anatomical landmarks in an adult South Gujarat population, the area where this information is scanty. This study was conducted using 100 dried human mandibles of unknown sex obtained from the Department of Anatomy, S.M. Institute of Medical Education & Research and Government Medical College, Surat. The parameters including size, shape, number, location and dimensions of mental foramen with respect to the surgically encountered anatomical landmarks were studied. In most of the cases the foramen was oval in shape and situated in the line with the longitudinal axis of the 2<sup>nd</sup> premolar tooth. Its usual opening was in a postero-superior direction.

**Key Words:** Mental Foramen (MF), Morphometry, Surgical landmarks, Dental Procedures.

### **Introduction:**

Mental Foramen (MF) is an important anatomical landmark to facilitate surgical, local anesthetic and other invasive procedures for dental surgeons performing periapical surgery in the mental region of mandible. Its location and the possibility that an anterior loop of the mental nerve may be present mesial to the MF and needs to be considered before any surgery in the foramina area in order to avoid any nerve damage. The MF is situated bilaterally on the anterolateral aspect of the mandible, down to alveolar margin. The mental nerve and vessels emerges through the mental foramen and supply sensory innervation and blood supply to the soft tissues of the chin, lower lip and gingiva (Sinnathamby, 1999; Berry et al, 2000). But the position of MF vary among racial groups and genders (Cutright et al, 2003; de Freitas et al 1976; Green, 1987). Despite the significance of MF, little attention has been given to the study of the morphology, most common location of foramen and associated anatomical characteristics in South Gujarat, hence this study has been conducted to investigate the number, size, shape, dimensions and location of MF with respect to the surgically encountered anatomical landmarks.

**Corresponding Author:** Dr. Deepa Rani Agarwal, S.M. Institute of Medical Education & Research, Near Sahara Darwaza, Umarwada Surat-395010

**Phone No.:** 09427657229, 02616599015

**E-mail :** deepaagrawal22@yahoo.com

### **Material and Methods:**

100 dried adult human mandibles with complete dentition and intact alveolar margin of unknown sex obtained from the Department of Anatomy, S.M. Institute of Medical Education & Research and Government Medical College, Surat, were used for this study. The shape, size, location, number of MF, direction of opening of mental foramen were measured on both sides of mandible by using digital Vernier caliper.

The shape of MF observed was either oval or rounded. Mean horizontal and vertical diameters were measured. Location of MF was identified by using following parameters: (1) Distance from mental foramen to mental symphysis; (2) Distance from mental foramen to alveolar margin and (3) Distance from mental foramen to inferior border of the mandible. The position of MF was noted in relation to mandibular teeth. The direction of opening of MF was recorded as postero-superior, superior, lateral, antero-superior, posterior or anterior (Phillips et al, 1990). A comparison of the mean values between sides was performed using the t-test, p-value<0.05 was considered statistically significant.

### **Observations:**

Morphometric features of 100 dried human mandibles revealed that the number of MF on each side was single in 97.4% cases, whereas double in 2.6% cases as shown in Fig.I. The shape of foramen was oval in 92% cases and rounded in 8% cases as seen in Fig. II.

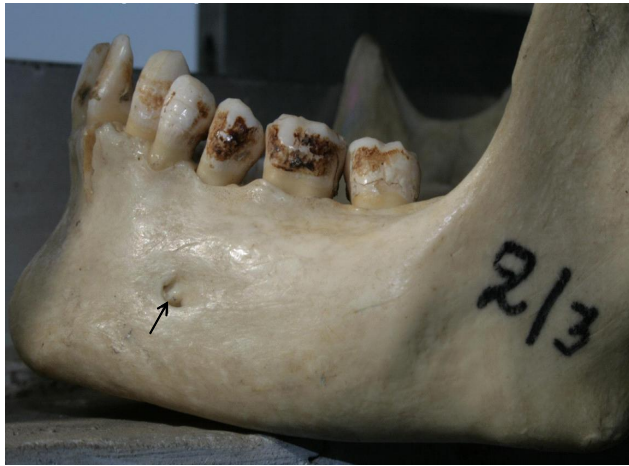

Fig. I: Showing double mental foraman.

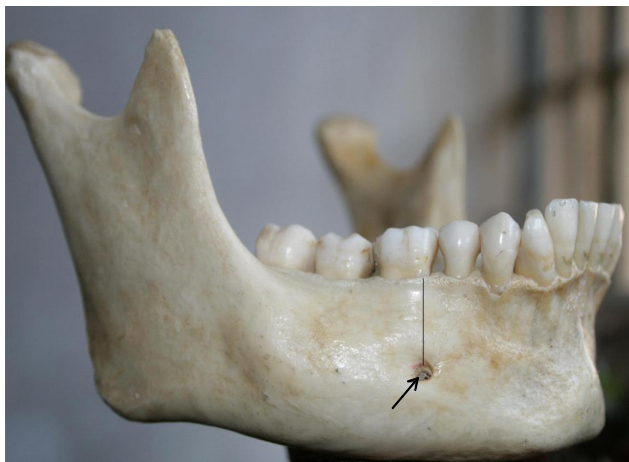


Fig. II: Showing rounded mental foraman and is in line with first molar teeth.

Mean horizontal diameter was 3.33mm on right side and 3.25mm on left side with range of 2.1-6.2mm, whereas mean vertical diameter was 2.15mm on right side and 2.13mm on left side with range of 1.8-3.1mm. The linear measurements of MF with respect anatomical landmarks are given in Table I. The position of mental foramen in relation to mandibular teeth on the two sides are shown in Table II. The most frequent position of foramen in relation to the teeth was in line with the longitudinal axis of 2<sup>nd</sup> premolar for both right (81.55%) and left (81.50%) sides. The second common position was in the line of 1<sup>st</sup> molar teeth (right 7.9%; left 7.8%) as shown in Fig. II, followed by in line between 1<sup>st</sup> & 2<sup>nd</sup> premolar (right 7.8%; left 7.6%); least common position was in the line between 2<sup>nd</sup> premolar & 1<sup>st</sup> molar teeth (right 2.7%; left 3.1%).

The direction of exit of the MF was postero-superior in 92%, followed by superior in 3.3%, laterally in 3.3%, and posterior in 1.4% of the mandibles.

Table I: Morphometric measurements of the mental foramen between two sides.

Characteristic	Right side (mean±SD)mm	Left side (mean±SD)mm
Distance between MF and symphysis menti	25.55±5.07	25.05±5.07
Distance between MF and alveolar margin	14.05±3.05	13.82±3.06
Distance between MF and lower border of mandible	12.16±3.04	12.11±3.11

Table II: Frequency of the location of mental foramen in relation to mandibular teeth between the two sides.

Location	Right side	Left side
In the line with the second premolar	81.55%	81.50%
Between second premolar and first molar	2.75%	3.1%
Between first and second premolar	7.8%	7.6%
In the line with first molar	7.9%	7.8%
In the line with the first premolar	0%	0%

## Discussion:

The precise identification of position of the mental foramen is important in both diagnostic and clinical procedures of the mandible. Clinically, mental nerve bundle emerging from the mental foramen may get injured during surgical procedures with resulting paresthesia or anesthesia along its sensory distribution (Phillips et al, 1990). Anatomically, the mental foramen is the opening of the mental canal. According to standard text books, mental foramen is most commonly situated between the apices of the first and second lower premolar (Sinnathamby, 1999; Berry et al, 2000). Although this is in accord with some European population, but this is an exception to other populations (Green, 1987; Phillips et al, 1990; al Jaser et al, 1998; Ari et al, 2005; Shankland, 1994; Ilayperuma et al, 2009). Racial variation in the position of the mental foramen is clearly demonstrated. The modal position of the mental foramen in Chinese was in the line with the second premolar whereas in Britishers, it was between the first and second premolars (Santini & Land, 1990). It was also interesting to note that the mental foramen was positioned more posteriorly in Blacks than in Whites (Cutright et al, 2003). However, the most common

position of mental foramen in the present study was in the line with the long axis of the second lower premolar followed by in the line with the first molar tooth. This was in agreement with previous studies on other Asians like, Asian Indians, Thai and Malay populations (Shankland, 1994; Ngeow & Yuzawati, 2003).

During the early prenatal life mental foramen is located in the alveolar bone between the primary canine and first molar (Kjaer, 1989). Therefore, it is speculated that positions other than the most common ones are due to a lag in prenatal development.

The opening of the mental canal was postero-superiorly in majority of the subjects (92%). This was in agreement with previous studies (Boonpiruk, 1975; Mwaniki & Hassanali, 1992). The mean horizontal diameter of 3.33 mm, observed in the present study is also consistent with the corresponding figures of 2.93mm observed in west Indians (Oguz & Bozkir, 2002), although it was smaller than the diameters of 5.03 mm reported for Nigerians (Olasoji et al, 2004).

The mean distance from the mental foramen to the symphysis menti in the present study was  $25.55 \pm 5.07$  mm on the right side and  $25.05 \pm 5.07$  mm on the left side (Ilayperuma et al, 2009). There was no significant side difference either in the position or the morphometry of the mental foramen in South Gujarat populations. From a clinical point of view, information regarding the mean distance from symphysis menti to mental foramen in a given population has a significant implication. Generally, the mental foramen is difficult to localize as there are no absolute anatomical landmarks for reference (Phillips et al, 1990). As the mental foramen can not be clinically visualized or palpated, in clinical situations, it is localized in relation to the lower teeth. However, clinically there may be instances where the mental foramen can not be localized in its modal position in patients without a reference tooth or malposition of tooth. In such cases, mental foramen can be accurately localized if the distance from the symphysis menti is known.

## Conclusion:

The present study reveals valuable insights on the information concerning the morphology of mental foramen in South Gujarat population. The knowledge of the distances from surgically encountered anatomical landmarks in the present study provide valuable information to dental surgeons that will facilitate effective localization of the neurovascular bundle passing through mental foramen thus avoiding

complications from local anesthetic, surgical and other invasive procedures.

## Bibliography:

1. al Jasser NM, Nwoku AL: Radiographic study of the mental foramen in selected Saudi population. *Danto maxillofacial Radiology*, 1998; 27(6): 341-343.
2. Ari I, Kafa IM, Basar Z, Kurt MA: The localization and anthropometry of mental foramen on late Byzantine mandibles. *Collegium Antropologicum*, 2005; 29(1) : 233-236.
3. Berry MM, Bannister LH, Standring SM: Nervous System. In: Gray's Anatomy-The Anatomical Basis of Medicine and Surgery. PL Williams, LH Bannister, MM Berry, P. Collins, M Dyson, JE Dussek, MWJ Feruson (Eds.); 38<sup>th</sup> Edn.; Churchill Livingstone, New York, 2000; pp1230-1249.
4. Boonpiruk N: Location of mental foramen in Thai skulls. *Journal of Dental Association Thai*, 1975; 25(6): 295-302.
5. Cutright B, Quillopa N, Schubert W: An anthropometric analysis of the key foramina for Maxillofacial surgery. *Journal of Oral Maxillofacial Surgery*, 2003; 61(3): 354-357.
6. de Freitas V, Madeira MC, Pinto CT, Zorzetto NL: Direction of the mental canal in human mandibles. *Australian Dental Journal*, 1976; 21(4): 338-340.
7. Green RM: The position of the mental foramen: A comparison between the Southern (Hong Kong) Chinese and other ethnic and racial groups. *Oral Surgery, Oral Medicine, Oral Pathology*, 1987; 63(3): 287-290.
8. Ilayperuma I, Nanayakkara G, Palahepitiya N: Morphometric Analysis Of the Mental Foramen in Adult Sri Lankan Mandibles. *International Journal Of Morphology*, 2009; 27(4): 1019-1024.
9. Kjaer I: Formation and early prenatal location of the human mental foramen. *Scandinavian Journal of Dental Research*, 1989; 97(1): 1-7.
10. Mwaniki DL, Hassanali J: The position of mandibular and mental foramina in Kenyan African mandibles. *East African Medical Journal*, 1992; 69(4): 210-213.
11. Ngeow WC, Yuzawati Y: The location of the mental foramen in a selected Malay population. *Journal of Oral Science*, 2003; 45(3): 171-175.
12. Oguz O, Bozkir MG: Evaluation and location of mandibular and mental foramina in dry, young, adult male, dentulous mandibles. *The West Indian Medical Journal*, 2002; 51(1): 14-16.
13. Olasoji HO, Tahir A, Ekanem AU, Abubakar AA: Radiographic and anatomic locations of mental foramen in Northern Nigerians adults. *The Nigerian Postgraduate Medical Journal*, 2004; 11(3): 230-233.

14. Phillips JL, Weller RN, Kulild JC: The mental foramen:  
1. Size, orientation and positional relationship to the  
mandibular second premolar. *Journal of Endodontics*,  
1990;16(5):221-223.
15. Santini A, Land MA: Comparison of the position of the  
mental foramen in Chinese and British mandibles. *Acta  
Anatomica*, 1990;137(3):208-212.
16. Shankland WE: The position of the mental foramen in  
Asian Indians. *Journal of Oral Implantology*,  
1994;20(2):118-123.
17. Sinnathamby CS: Last's Anatomy: Regional and  
Applied. 10<sup>th</sup> Edn.; Churchill Livingstone, Edinburgh,  
1999;pp506.